

Atraumatic soft silicone foam exudate transfer dressings*¥ efficacy in Epidermolysis Bullosa: Case series

*Mepilex® Transfer
¥ Mepilex® Transfer Ag

Mendes, Luciana ^a; Pinheiro, Suyanne ^b; Duque, Carla ^c; Carmen, Mirelly ^d

^a WOCN Nurse, Sales Manager; ^b WOCN Nurse, Sales Representative; ^c WOCN Nurse, Sales Representative; ^d WOCN Nurse, Sales Representative, Cobermed® Brazil
^{a, b, c} - Mölnlycke® Health Care Brazil

Introduction

Bullous epidermolysis (EB) is defined as a rare, hereditary skin condition that includes a group of diseases characterized by the occurrence of blisters on the skin and mucous membranes. Vesicles and blisters usually develop as a result of mechanical pressure or friction, but may occur spontaneously, with a highly variable clinical severity, and may be of autosomal recessive or autosomal dominant nature. There are four main groups that are subdivided according to the inheritance pattern, lesion morphology, affected areas, histological level of skin separation and type of mutations. Due to the treatment complexities atraumatic soft silicone dressings had been recommended for the management of patients with EB.

Objective

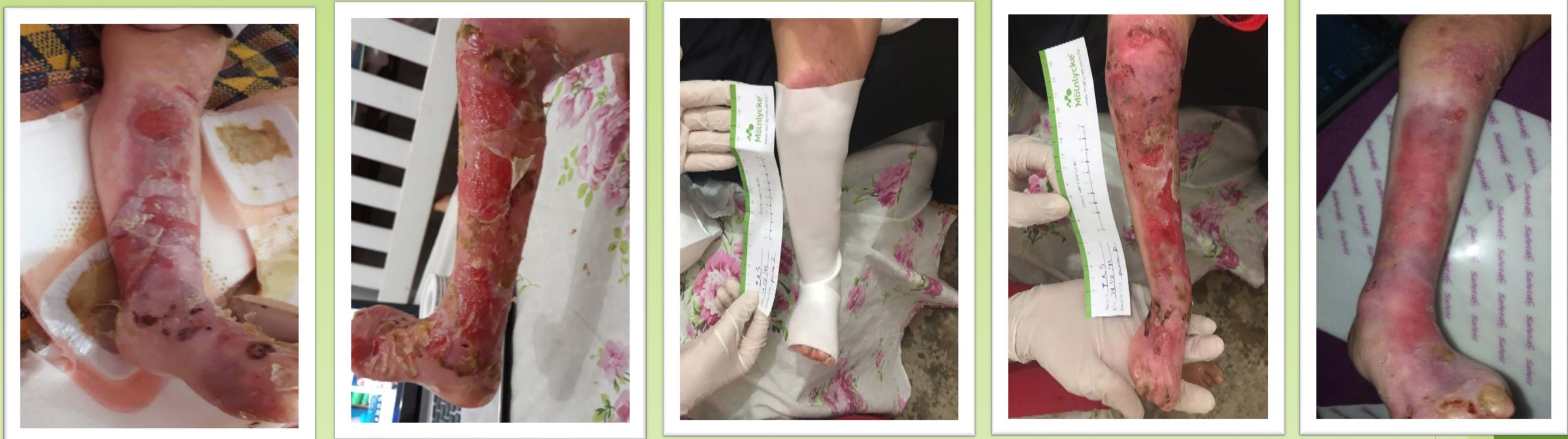The aim of these case studies was to evaluate the safety and performance of atraumatic soft silicone foam exudate transfer dressings*¥ in the management of patients with EB.

Methods:

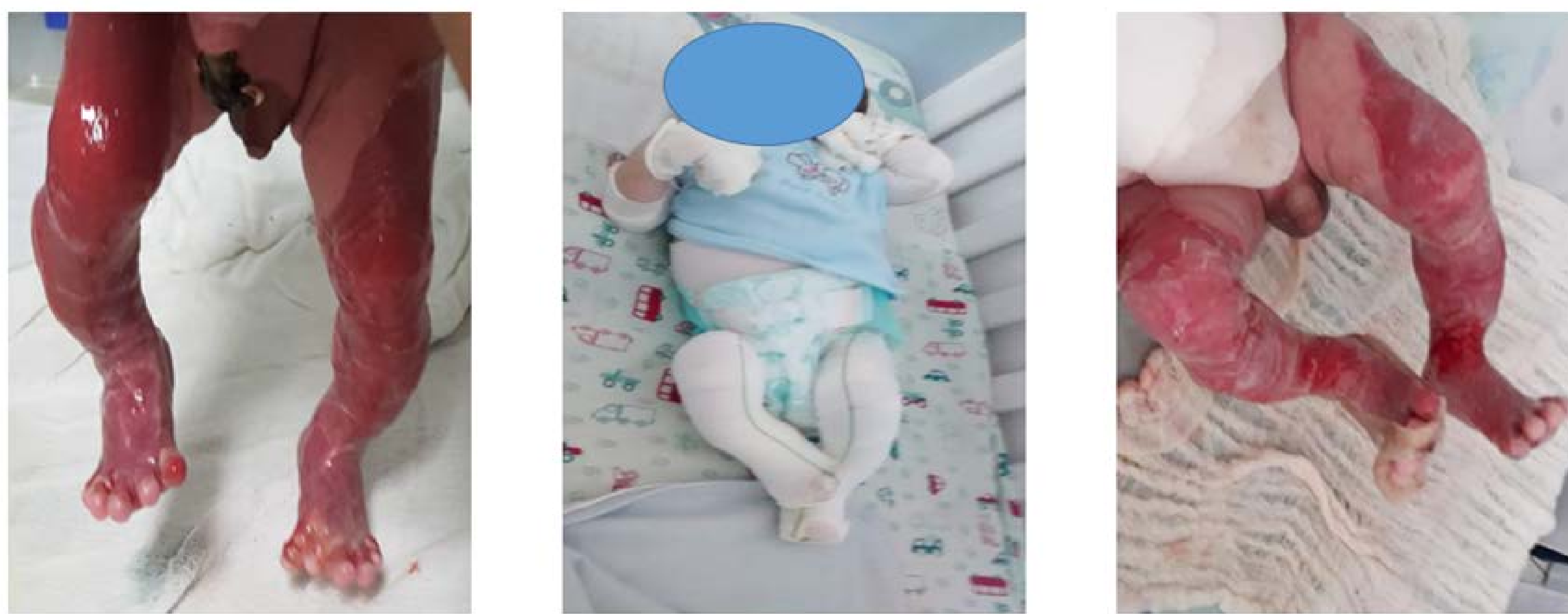Descriptive case series reporting on the three Epidermolysis Bullosa cases treated in Brazil in 2019. All three patients were treated with the soft silicone foam exudate transfer dressings*¥ for the wound management and skin lesions. A follow-up questionnaire for home care was completed by caregivers, and the photographs to capture the progress of blisters were taken throughout the whole treatment period.

Results:

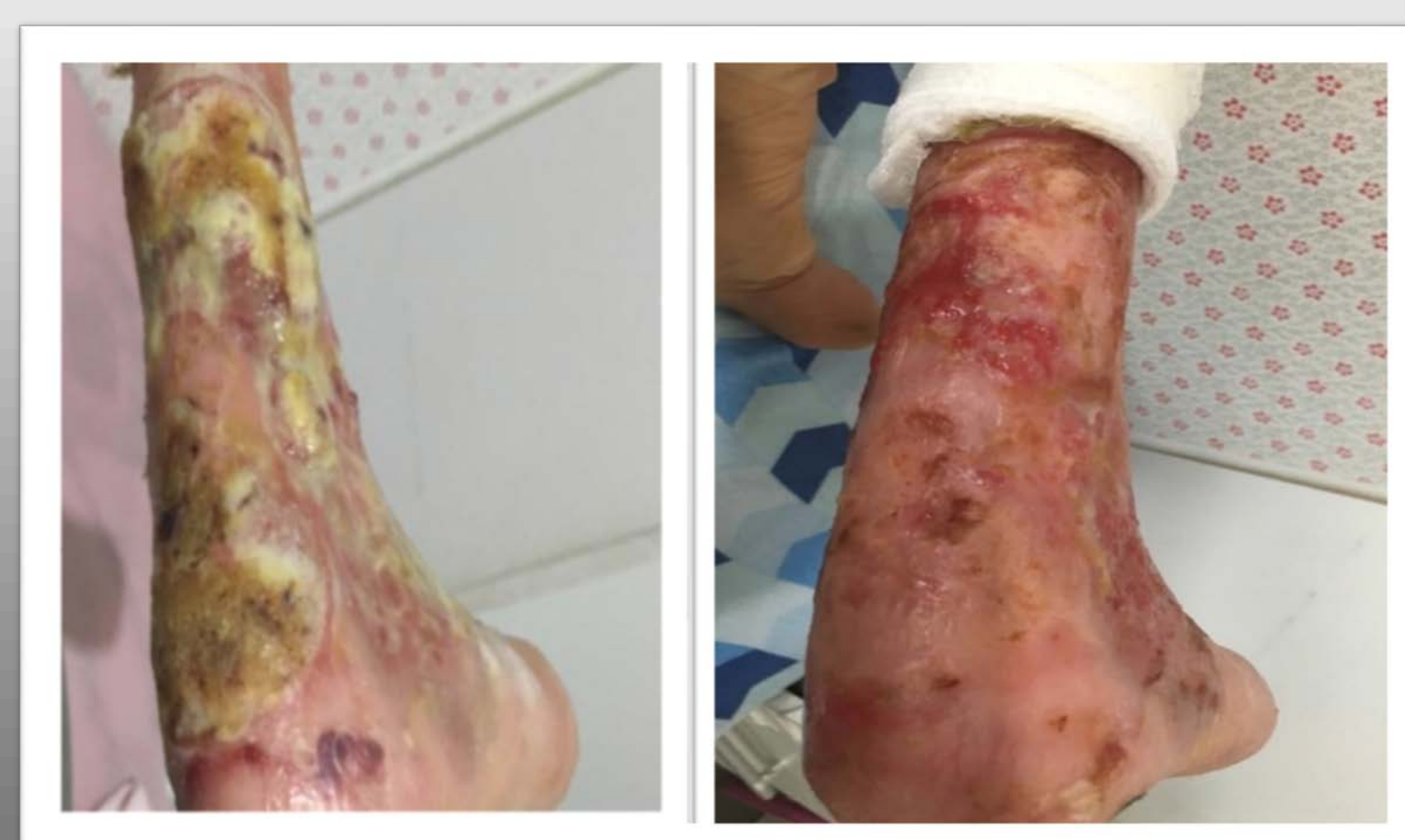Case 01: A 2-year old female patient with dystrophic EB presented skin lesions on the right and left lower limbs with excess exudate and an unpleasant odour. The patient had previously used a silicone gel absorbent foam and hydrofiber dressings without a positive response to the treatment regimen. During the initial visit, the wounds were flashed with 0.9% saline solution and subsequently covered by a soft silicone foam exudate transfer dressing* and bidirectional tubular mesh. Dressing changes were performed every 2 days with good clinical progress. In the opinion of the caregiver, the quality of life of the patient significantly improved, to a great extent, due to the fact that the dressings were comfortable to wear and perform physical activity, such as walking safely without assistance.



Case 02: This is a case report of a newborn patient diagnosed with aplasia cutis congenita (ACC) and EB at birth. No family history of congenital malformations was reported. The patient was diagnosed with ACC and EB due to the absence of the skin on the lower limbs accompanied by blisters on the upper limbs, neck and gluteal regions. Wound care and dressings had been performed every 48 hours after bath. On the fifth day after birth the soft silicone foam exudate transfer dressing* had been used as a primary cover for the areas without skin and blisters, whereas an absorbent dressing served as a secondary cover. These dressings were left intact for 5 days. The second dressing change was performed on the eleventh day after birth, thereafter the patient had been discharged from hospital on the same day. During the use of the Dressing* on the newborn for one week at hospital, the patient's behavior was very close to that of a healthy infant. Medical staff reported that the Dressing* was comfortable to wear; patient's acceptance of breastfeeding improved; and there were fewer expressions of pain in the newborn during the whole period of hospital stay and hygiene procedures.



Case 03: A 39 year-old female patient diagnosed with EBDR and secondary carcinoma presented a skin lesion on the right lower limb. The skin lesion had a large amount of serous exudate, necrotic area and a fetid odour. At the start of the treatment period the lesion was debrided and the silver sulfate-impregnated soft silicone foam exudate transfer dressing¥ was applied. Dressing changes were performed every 2 days, for the period of 2 months. At the end of this period good results were achieved and the healing process was promoted.



Conclusion

These case series suggest that the soft silicone foam exudate transfer dressings*¥ with and without silver are both tolerated and perform well in the wound management of patients with Epidermolysis Bullosa. These dressings considerably promoted healing not causing additional pain and trauma to the existing lesions, and protected their edges and the surrounding skin.

Acknowledgement:

Case 01: Photographs and case notes kindly supplied by Ceara Epidermolysis Bullosa Association, Fortaleza, Ceará, Brazil;
Case 02: Photographs and case notes kindly supplied by Dr Mirelly Carmen, WOCN, Cobermed, Maceió, Alagoas, Brazil;
Case 03: Photographs and case notes kindly supplied by Pernambuco Epidermolysis Bullosa Association, Recife, Pernambuco, Brazil.

Epidermolysis Bullosa: Case Report

Mendes, Luciana, WOCN Nurse, Sales Manager, Mölnlycke® Health Care Brazil

Introduction

Epidermolysis bullosa (EB) describes a rare complex group of inherited blistering disorders. There are four categories of EB, defined by the level of cleavage at the dermal/epidermal junction: EB simplex (EBS), junctional EB (JEB), dystrophic EB (DEB) and Kindler syndrome (1).

In the recent best practice guidelines for skin and wound care in patients with EB published in 2017 it is noted that the common factor in all types of EB is the tendency for skin and mucous membranes to blister or shear away in response to minimal every day friction and trauma. The guidelines also state that the severity of EB varies from mild superficial blistering affecting the hands and feet to life-threatening conditions and death due to vast mucosal blistering in the gastrointestinal and upper respiratory tracts, people with more severe forms of EB experience recurrent blistering with a tendency to chronic wounds and subsequent stenosis and strictures (2).

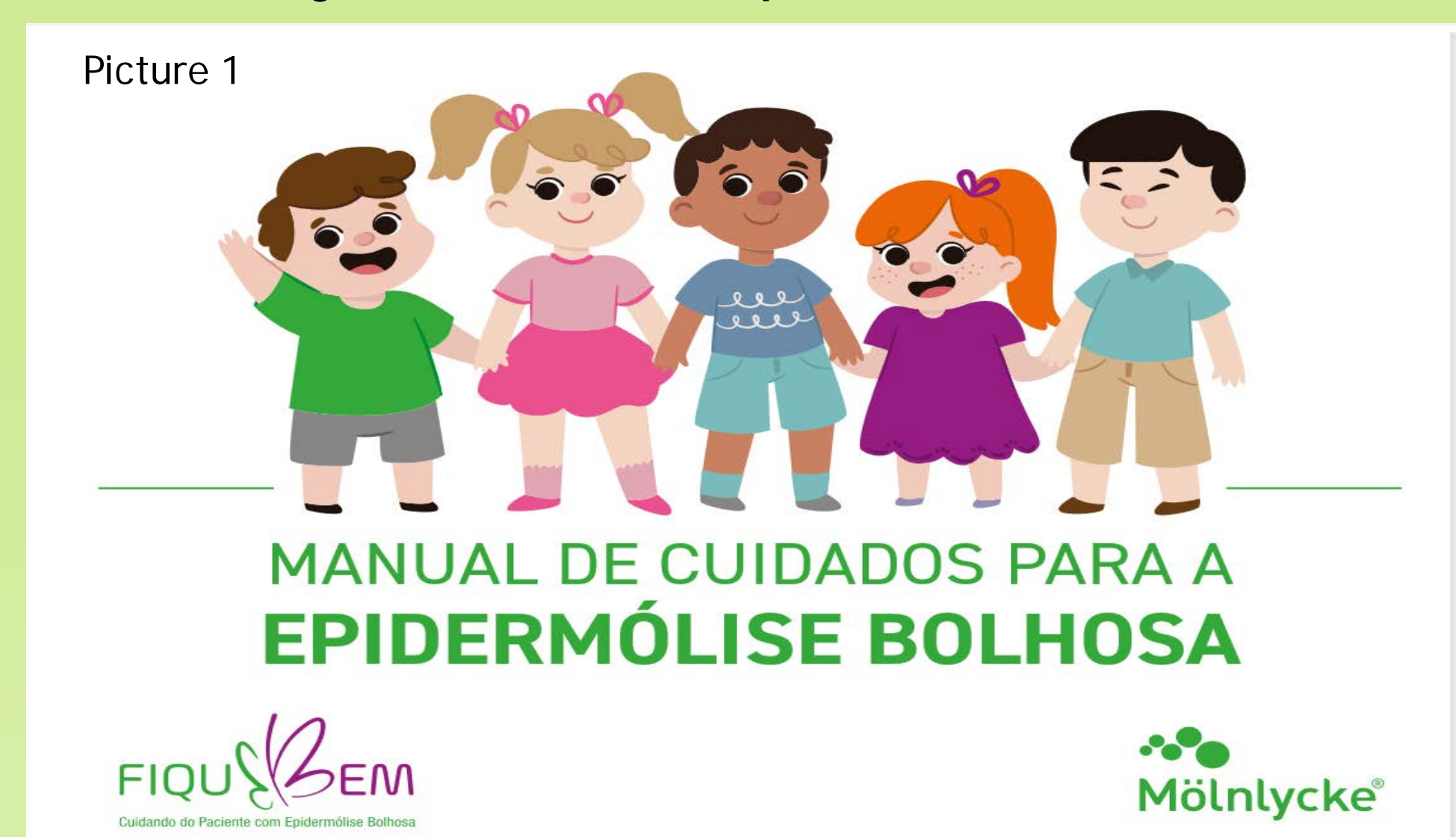One of the key recommendations of the best practice guidelines is "Atraumatic dressings should be used to prevent further blistering, skin and wound be damage." (2).

Objective

The aim of this observational study was to develop a practical aid manual for healthcare professionals and family members of patients with EB which would help them in daily care of patients with EB, describe common strategies and challenges.

Methods

This is an observational descriptive study performed in the home care settings in four patients with genetically-determined EB in Brazil (one young child, one neonate and two adult patients). Home visits were conducted between February and August 2018. In addition, medical records and mothers' and family diaries were analysed. Common successful daily care strategies and challenges were identified and served as the ground for creation of a practical care manual for HCPs and family members of patients with EB.



Reference: 1. Fine, J.D., Bruckner-Tuderman, L., Eady, A.J., Bauer, A., Bauer, W., Has, C., Heagarty, A., Hintner, H., Hoymanian, A., Jonkman, M.F., Leigh, I., Marinkovich, M.P., Martinez, A.E., McGrath, J.A., Mellenio, J.E., Moss, C., Murrell, D.F., Simiizu, H., Uitto, J., Woodley, D., Zambruno, G. Inherited epidermolysis bullosa: updated recommendations on diagnostic and classification. *Journal of the American Academy of Dermatology* 2014;70(6):1103-1126.

2. Denyer, J., Pillay, E., Clapham, J. Best practice guidelines for skin and wound care in epidermolysis bullosa. An International Consensus. *Wounds International* 2017. Available at: http://www.debra-international.org/fileadmin/media_data/4_DEBRA_International/CPGs/Guidelines/International_Consensus_Best_Practice_Guidelines_Skin_and_Wound_Care_in_Epidermolysis_Bullosa.pdf (accessed online 09 January 2020).

Results

The following examples of the successful care strategies and main challenges were identified:

- ▶ Blister and wound management caused by the disease was proven to be the major challenge for HCPs and families due to often inaccessible advanced wound dressings and appropriate diet with high nutrient components.
- ▶ Multi-disciplinary care of a neonate with EB already at birth was not always available due to the fact that EB was not diagnosed by the ultrasound examination, whereas genetic testing in the prenatal period was rarely done.
- ▶ The mode of delivery method can affect the severity of blisters and other injuries in the neonate presented at birth and should be carefully considered by HCPs.
- ▶ The routine procedures which were usually performed after birth could lead to the worsening of the injuries in the newborn and prolonged hospital stay.
- ▶ In adult patients with EB, the challenges were similar. In addition, adult patients suffered from psychosocial isolation, prejudice and exclusion from socialization. Patients with EB were often stigmatized as the "wounded". Secondary carcinoma remained the major cause of death of patients with severe EB.

These findings demonstrated the importance of the locally-tailored guidance on daily care of patients with EB aimed at healthcare professionals and families. The practical manual based on this experience (Picture 1) may help families and professionals to offer better assistance in the care of patients with EB.

Conclusions

These observations reinforce the hypothesis that often worsening of the condition of patients with EB can be explained by the lack of information on the specifics of EB available to parents and HCPs. Most patients suffer from the lack of access to effective treatments and medical devices such as atraumatic wound dressings and special diet among others.

This is the obligation of HCPs to educate home care nurses, medical students, general public, parents and families, through materials such as the manual that was developed based on this experience.

A CROSS-SECTIONAL OBSERVATIONAL STUDY OF PATIENTS WITH EPIDERMOLYSIS BULLOSA TO UNDERSTAND USAGE PATTERNS OF SILICONE-BASED DRESSINGS AND FIXATION DEVICES

Kristina Blom ^a, Jane Clapham ^b, Viktoria Korner ^c and Ulana Pawlak ^d.

^a Ph.D., Clinical Development Manager and Evidence Strategist, Mölnlycke® Health Care, Gothenburg, Sweden

^b Lead EB Nurse Specialist at Guy's and St Thomas' NHS Foundation Trust, London, United Kingdom

^c Clinical Development Manager and Evidence Strategist, Mölnlycke® Health Care, Gothenburg, Sweden

^d MD, Global Medical Affairs and Safety Manager, Mölnlycke® Health Care, Gothenburg, Sweden

Introduction:

Epidermolysis bullosa (EB) is a group of rare genetic skin conditions characterised by fragile skin and recurrent blisters (1). In EB, the two skin layers lack the anchors that hold them together, with friction or shearing, causing blisters and painful sores (2).

Silicone-based dressings and fixation products are widely used for patients with EB (3). With new strategies being developed to manage EB wounds, patient feedback is a vital source of information on which the performance of products can be gauged.

Aims:

A study was undertaken to seek the views of users to assess the performance and safety of a range of Mölnlycke® products including wound contact layers (Mepitel®, Mepitel® One), absorbent foam dressings (Mepilex®, Mepilex® Border Lite, Mepilex® Lite), exudate transfer dressings (Mepilex® Transfer), fixation tape (Mepitac®), and tubular retention bandages (Tubifast®).

Materials and Methods:

Patients were each asked to complete a questionnaire to record their age, gender, EB type, and the Mölnlycke® products that they had used. They were also asked to rate the performance and safety of the products using balanced Likert-like type scales.

Results:

DEMOGRAPHY. Nineteen patients completed the survey. Six (32%) patients were <10 years old, 4 (21%) were between 10 and 18 years old, 8 (42%) were between 19 and 50 years old, and 1 (5%) was >50 years old. Six (32%) respondents were male, and 13 (68%) were female.

DIAGNOSIS. Six (32%) respondents were diagnosed with EB simplex, 3 (16%) with Junctional EB, and 10 (53%) with Dystrophic EB. None was diagnosed with Kindler's syndrome.

DRESSING PRODUCTS. Collectively, the participants were able to give feedback on all products.

DRESSING CHANGE FREQUENCY. This ranged from 4 times per day up to once a week (average 1-2 per day). The dressing change time ranged from 5 minutes to 4 hours (average 1 to 2 hours).

EASE OF USE. The products were rated as being easy to use, compatible with other topical treatments and, in the case of the foam dressings, good absorbents.

TOLERABILITY. All dressings were well tolerated. Although, two patients with Junctional EB experienced pain when using Mepilex®XT, a silicone foam dressing not part of the survey.

MOST USED PRODUCT. Mepilex® Border Lite had been used by most patients, 17 (89%).

PERFORMANCE AND SAFETY. These are shown in Figures 1 to 8.

Conclusion:

The survey indicates that the silicone-based dressings and fixation devices used by the respondents are both tolerated and perform well. The findings also highlight the importance for patients to understand the design features of different dressings to ensure that dressing choice is aligned with the needs and wishes of users.

References:

1. Fine J-D, Bruckner-Tuderman L, Eady RAJ, Bauer EA, Bauer JW, Has C, et al. Inherited epidermolysis bullosa: Updated recommendations on diagnosis and classification. *J Am Acad Dermatol.* 2014;70(6):1103-26.
2. Graham T, Sooriah S, Giampieri S, Box R, Grocott P. Iterative codesign and testing of a novel dressing glove for epidermolysis bullosa. *Journal of Wound Care.* 2019;28(1):5-14.
3. Denyer J PE, Clapham J. Best practice guidelines for skin and wound care in epidermolysis bullosa. *Wounds International.* 2017.

Fig. 1. Do you feel pain when you remove the product?

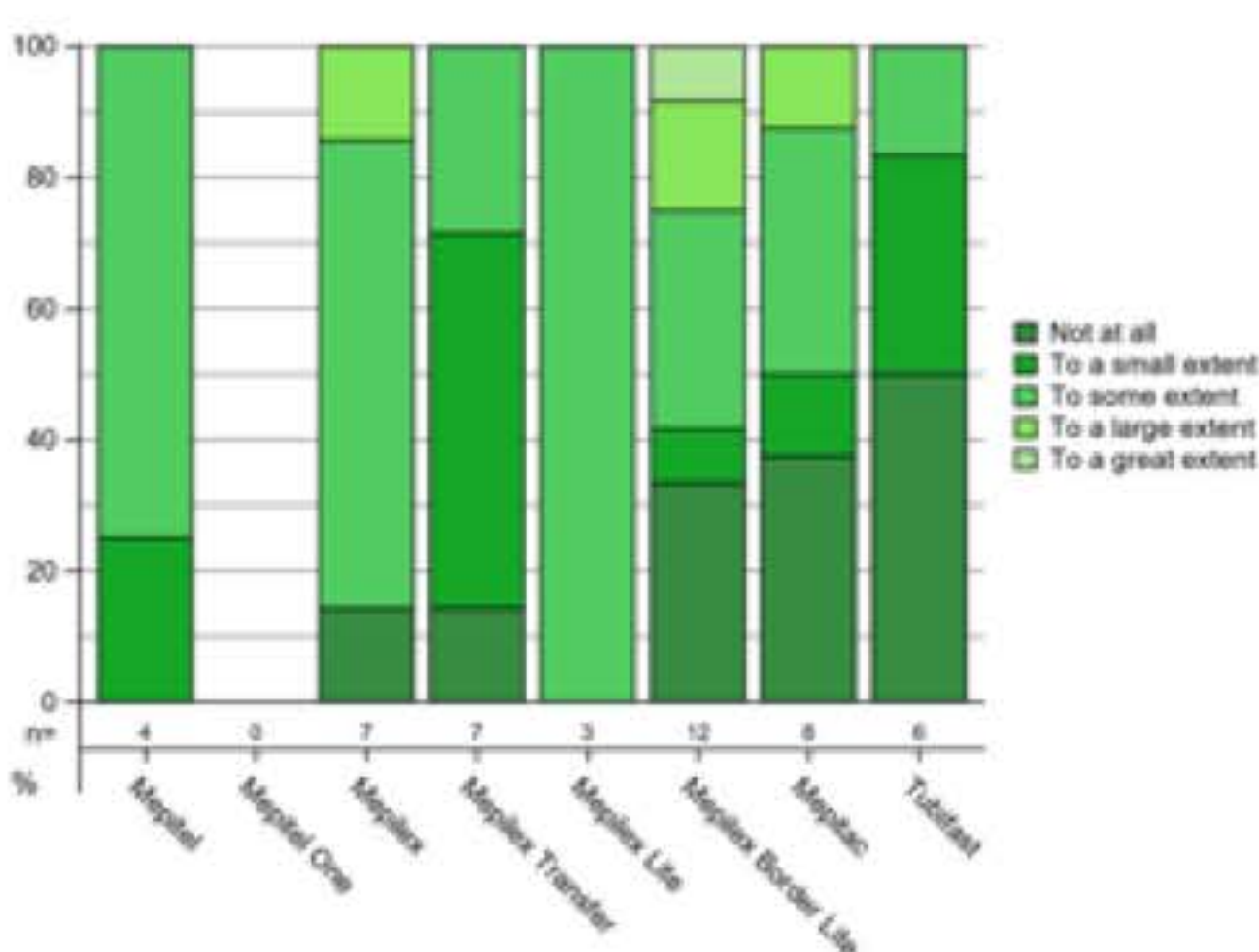


Fig. 2. Do you see any bleeding when you remove the product?

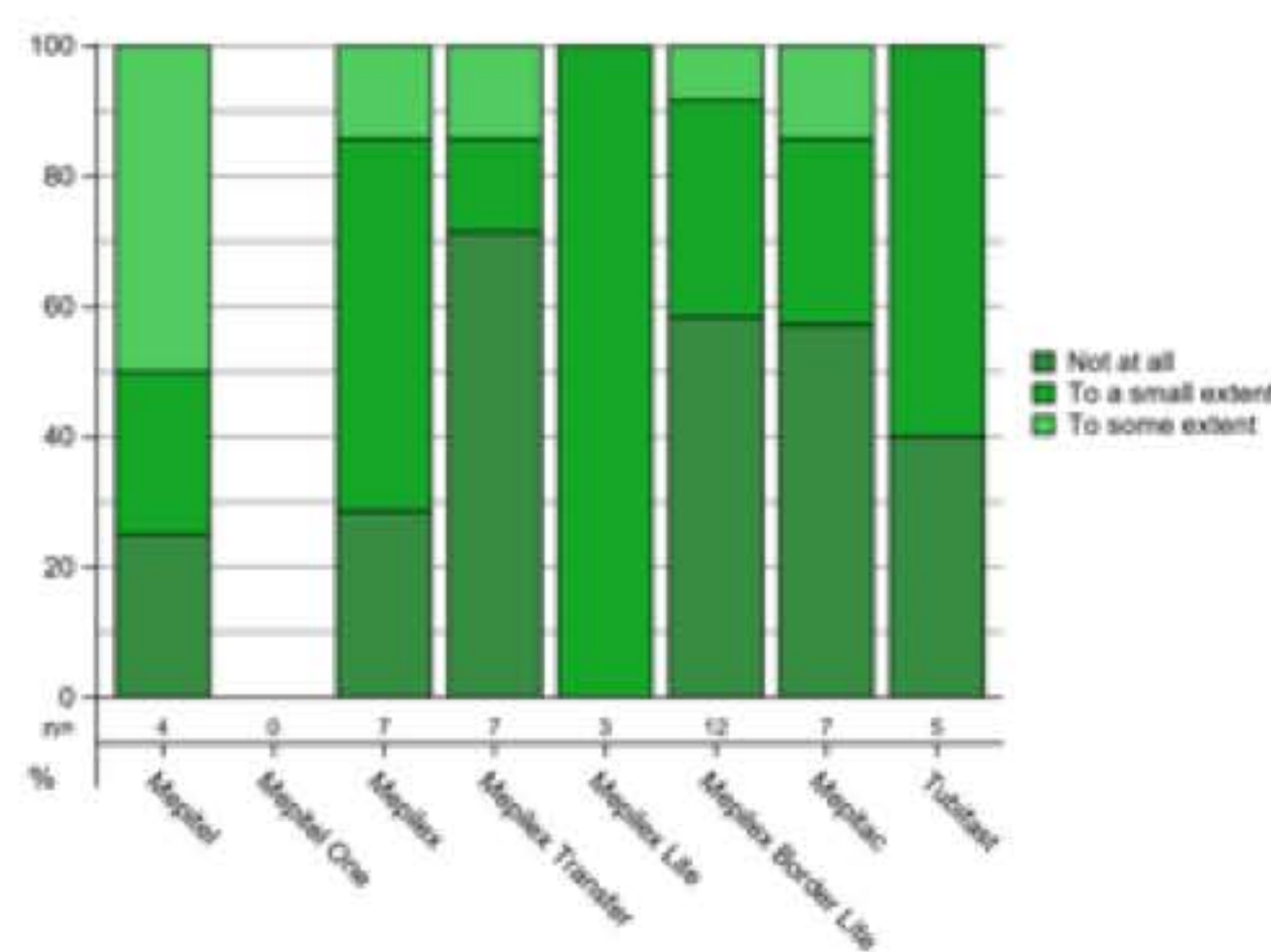


Fig. 3. Does the surrounding skin have blisters after you have used the product?

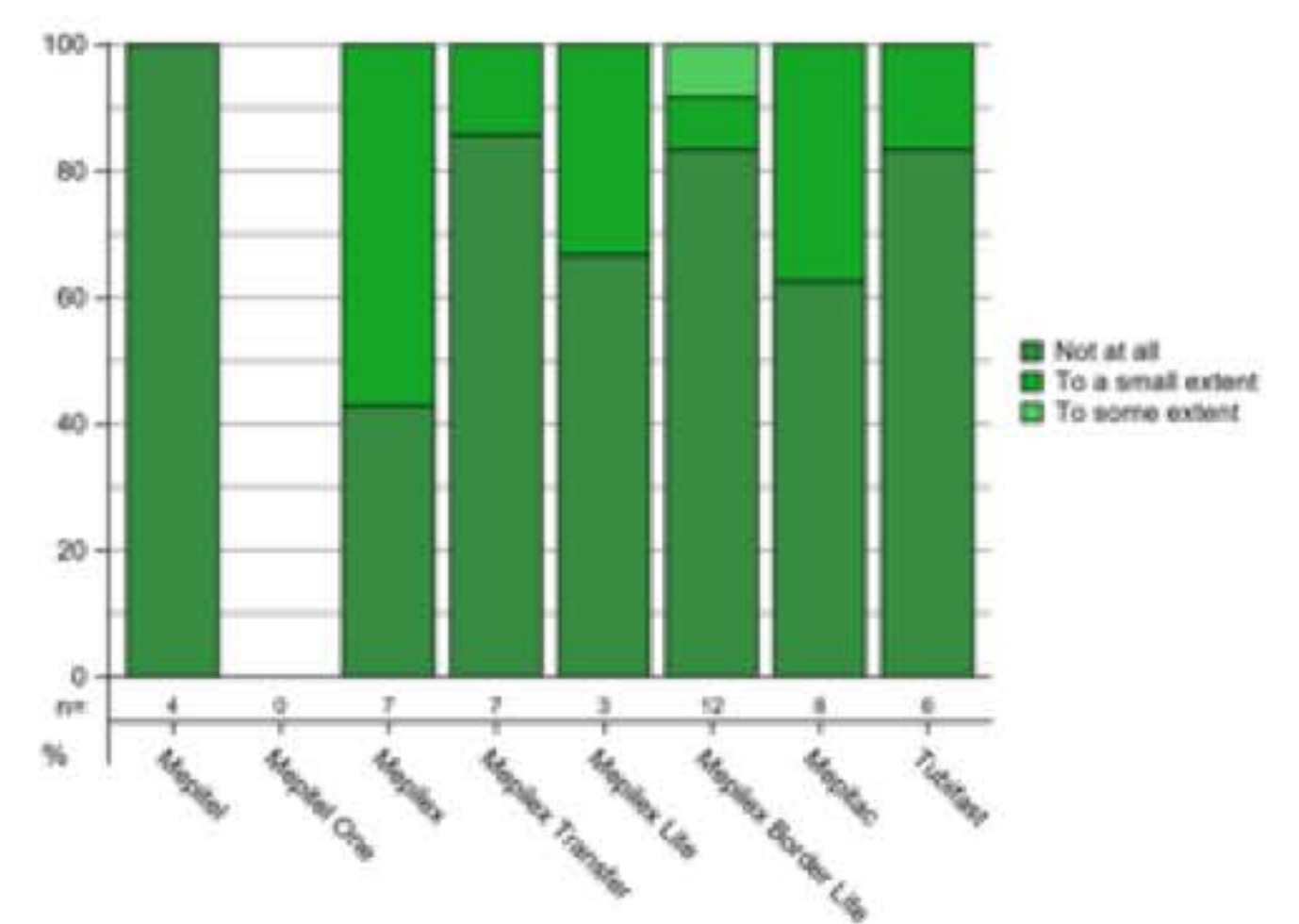


Fig. 4. Does the skin look moistened after you have used the product?

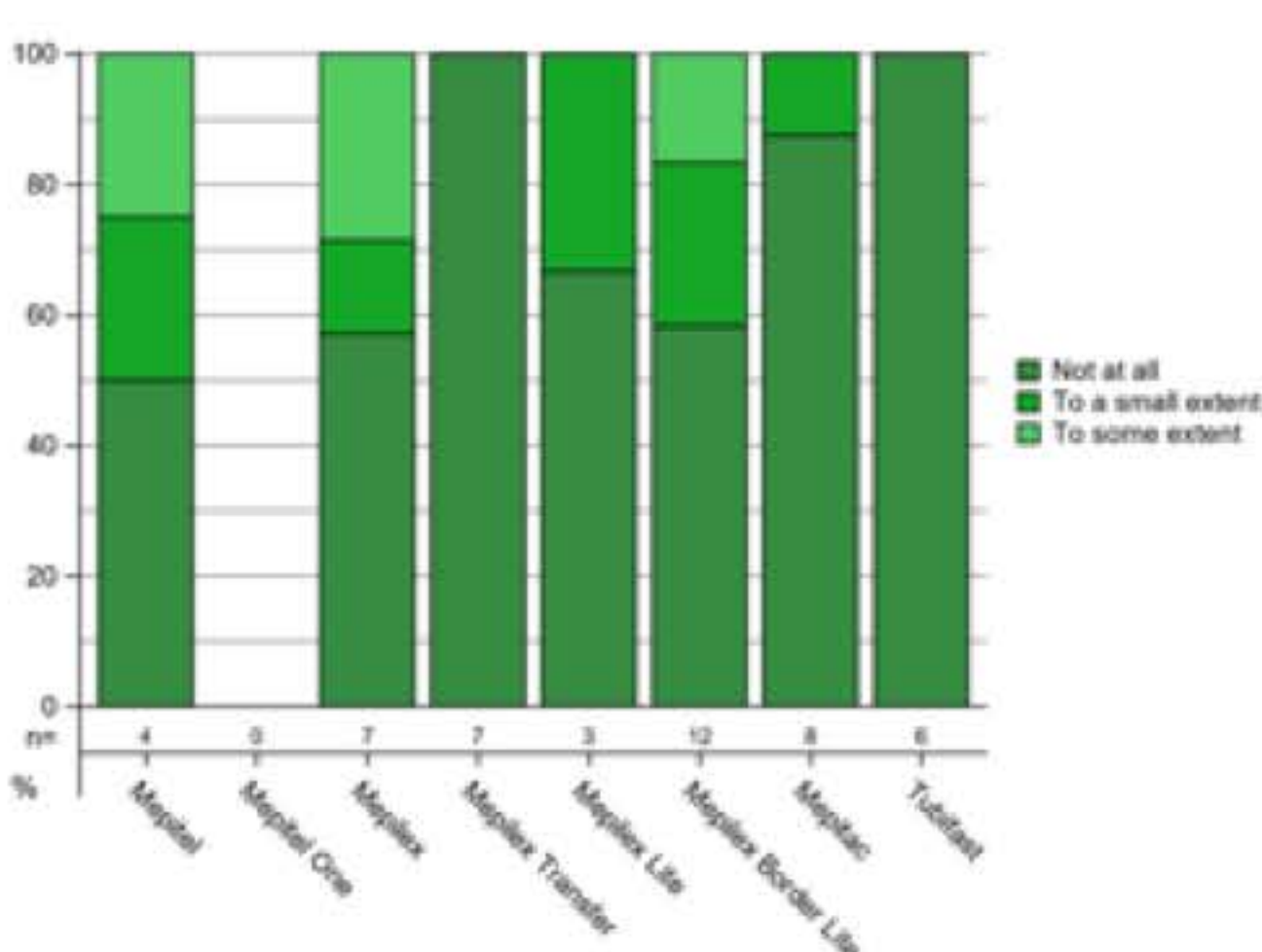


Fig. 5. Do you see any pieces from the product left in the wound?

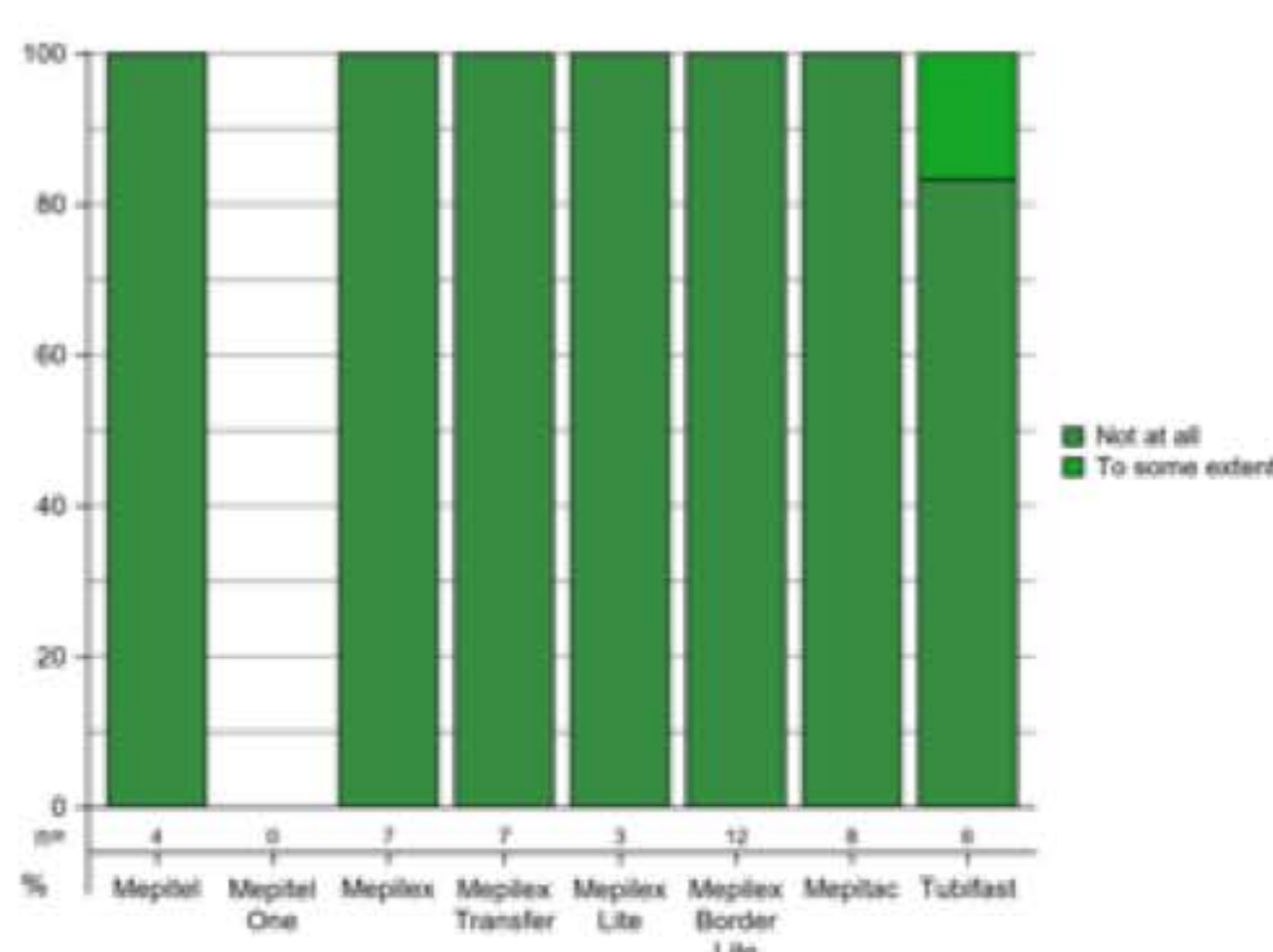


Fig. 6. Do you think the product does not stay in place where it was applied?

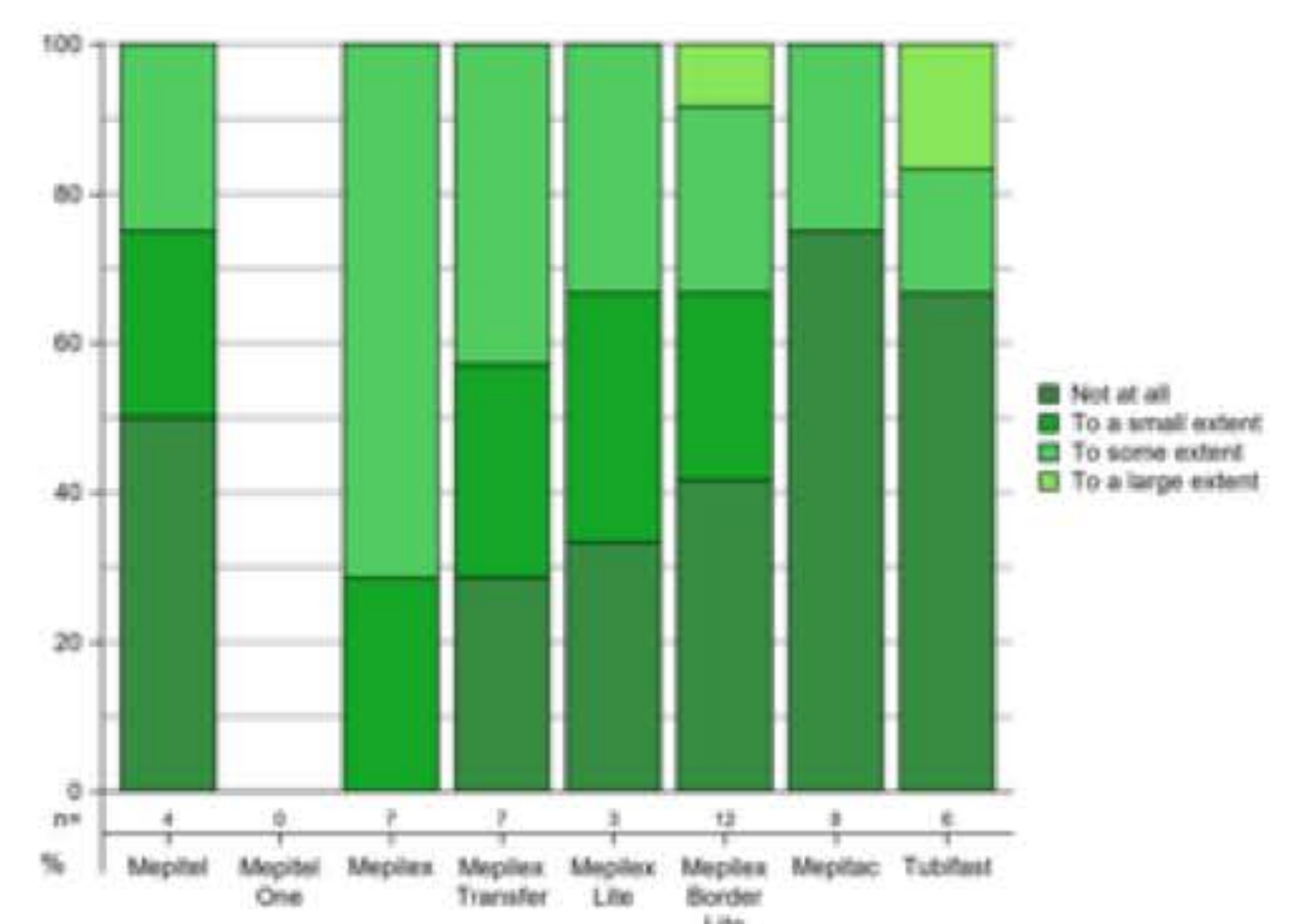


Fig. 7. Do you think the product increases any eventual heat that you may experience?

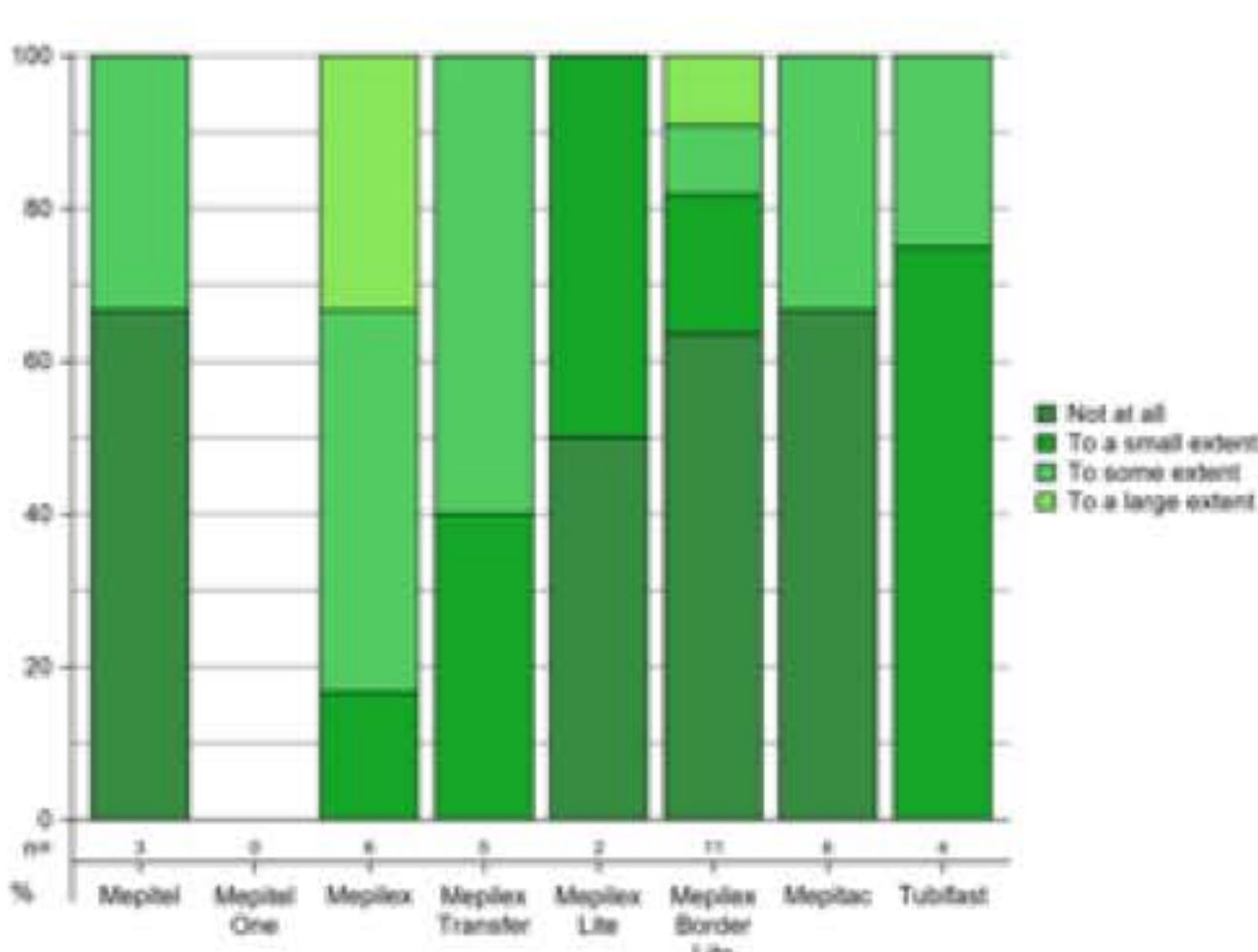
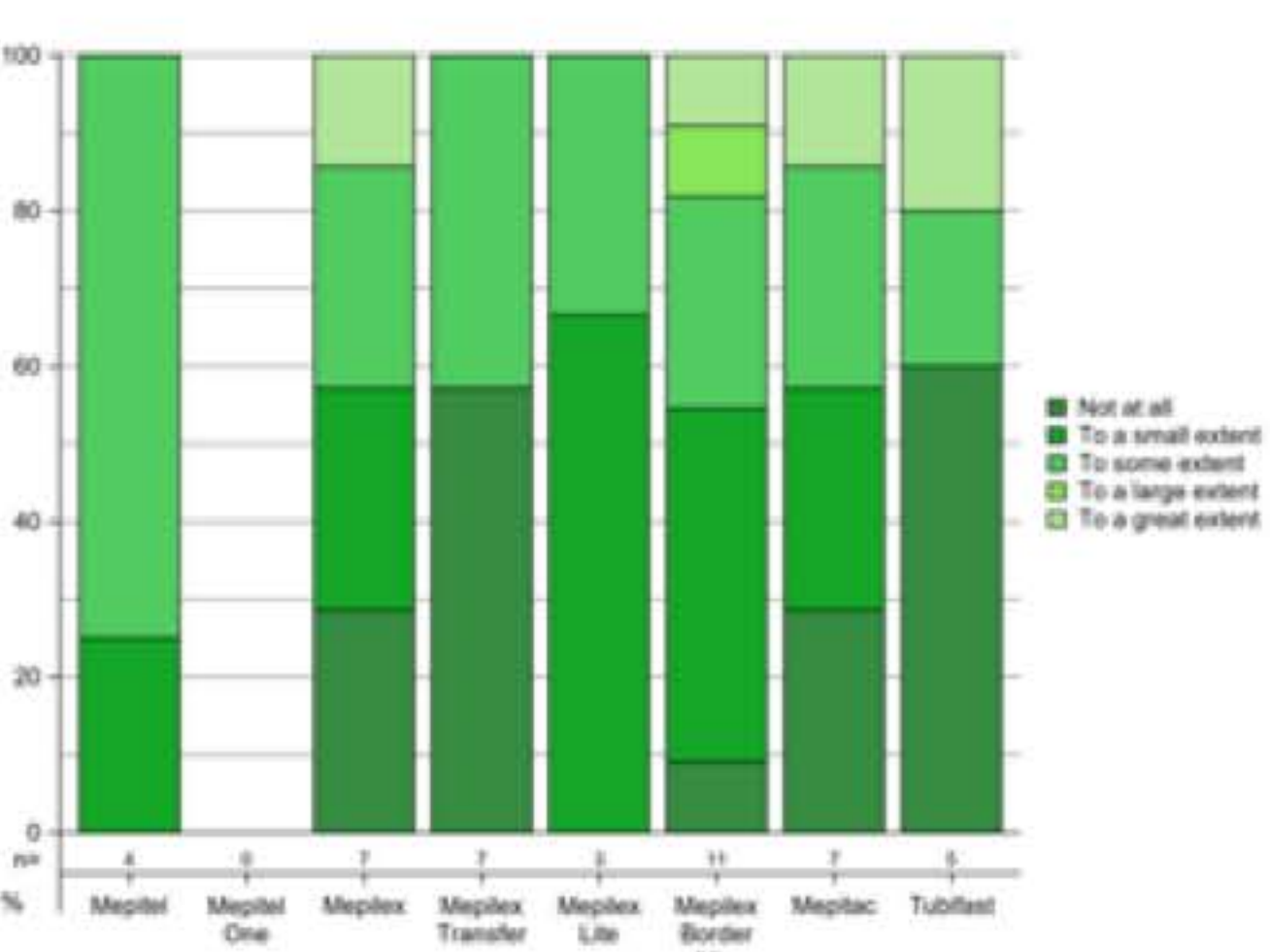


Fig. 8. Do you think that the product sticks to the wound?



SILICONE-BASED DRESSINGS AND FIXATION DEVICES IN THE MANAGEMENT OF EPIDERMOLYSIS BULLOSA: EVIDENCE REVIEW UTILISING THIRTY YEARS OF DRESSINGS WITH SAFETAC® TECHNOLOGY.

Ulana Pawlak ^a and Mark F. Rosenberg ^b

^a MD, Global Medical Affairs and Safety Manager, Mölnlycke® Health Care, Gothenburg, Sweden

^b Medical Writer, Medical and Economic Affairs, Mölnlycke® Health Care, Gothenburg, Sweden

Introduction: Epidermolysis bullosa (EB) is a group of rare genetic skin conditions characterised by fragile skin and recurrent blisters, which has a huge impact on patients both physically and emotionally.¹ There are four categories of genetically determined EB (ICD-11) defined by the cleavage level at the dermal/epidermal junction: EB simplex (EC30), Junctional EB (EC31), Dystrophic EB (EC32) and Syndromic EB including Kindler syndrome (EC33).¹ EB is associated with fragility of the skin, mucous membranes and blisters formation.² Complications such as secondary infections, malignancies, scar formation with deformities due to trauma, and chronic inflammation can often be prevented by appropriate blister management.³⁻⁵ EB-related wounds pose challenges for dressing selection. The removal of adherent wound dressings on EB skin can lead to additional pain and trauma to the wound-bed and peri-wound area.^{6,7} Over thirty years ago, Mölnlycke® Health Care (thereafter Mölnlycke®)⁸ introduced its proprietary silicone-based Safetac® dressing technology to overcome these issues across a wide range of wound types, including EB.² These dressings can mould to the contours of the wound and its anatomical location.⁹ Consequently, dressings with Safetac® can be applied and reapplied without causing damage to the wound or skin-stripping, as well as minimising pain on removal.^{10,11} These include a variety of dressings such as absorbent foam dressings, Mepilex®, Mepilex® Lite, Mepilex® Border Lite; exudate transfer dressings, Mepilex® Transfer; wound contact layers, Mepitel®; and fixation devices such as Mepitac® and Tubifast®. We highlight the long and safe experience of Mölnlycke® dressings on EB patients, supported by over 30 years of international clinical exposure to dressings with Safetac® technology.

Aims: To review the reported clinical outcomes associated with the use of Safetac®-based dressings and fixation devices and correlate the type of dressing device for specific types of EB or anatomical locations, where possible. We describe clinical patterns and estimate patient exposure, i.e. number of patients who have used Mölnlycke® Safetac® dressings and fixation devices.

Materials and Methods: A systematic literature search summarising the evidence on Mölnlycke® dressings and fixation devices concluded in January 2020. Electronic searches of bibliographic databases (Pubmed, MEDLINE, National Library of Medicine, Bethesda, USA; EMBASE, Elsevier BV, Amsterdam, Netherlands; CINAHL, Cinahl Information Systems, Glendale USA) and Internet sites (Cochrane Library; World Wide Wounds) were supplemented with manual searches of conference proceedings and journals of relevance to wound management.

Results: Due to the rarity of EB, it is challenging to conduct statistically valid studies to provide evidence to support the efficacy of any particular wound management strategy. Generally, it is suggested that silicone-based foam dressings can be used for superficial erosions, and for protection from friction and shear forces. Soft silicone contact layers are suitable for ulcers, whereas a thin silicone foam dressing with or without an exudate transfer layer is preferred for the prevention of digital webbing.² Non-adherence to the wound bed is recognised as a critical feature determining the choice of dressings. The soft silicone contact layer is reported to significantly alleviate pain and anxiety during dressing changes in several case studies involving children.

Table 1 summarises a selection of the EB-related cases involving the use of Safetac®-based dressings and fixation devices reported in the literature. We have also evaluated clinical specifics of product use, such as the choice of particular dressings for certain types of EB or anatomical locations.

In Table 2, we estimated dressings and fixation devices exposure worldwide. This table shows the Safetac® technology and Mepitel® being on the market the longest for over 30 years among the modern advanced dressings.

Conclusions: EB is a challenging condition which requires multi-disciplinary and wound specialist care with medical devices that are designed to minimise pain and trauma to the wound bed. Numerous published case studies demonstrate that the silicone-based dressings and fixation devices performed well, alleviated pain, and improved clinical outcomes in patients with EB and related bullous conditions. Mölnlycke® dressings offer a good solution for patients with EB who have very fragile skin and need to cover their blisters with dressings and mostly change those daily. The good experience with EB is based on the usage of dressings with Safetac® technology on a wide range of wound types over 30 years.

References:

1. Fine, J.-D. *et al. J Am Acad Dermatol* **70**, 1103-26, (2014).
2. Denyer J, P. E., Clapham J. *Wounds International*, (2017).
3. Bello, Y. M. *et al. Clinics in Dermatology* **21**, 278-82, (2003).
4. Diedrichson, J. *et al. Handchir Mikrochir plast Chir* **37**, 316-22, (2005).
5. Bruckner-Tuderman, L. *Dermatologic Clinics* **28**, 107-14, (2010).
6. Hollinworth, H. *et al. Journal of Wound Care* **9**, 369-73, (2000).
7. Denyer, J. *Seminars in Neonatology* **5**, 321-4, (2000).
8. Mölnlycke. Mölnlycke Health Care AB Sweden.
9. Cooper, P., Gray, D., Russell, F., Stringfellow, S. *Wounds UK* **2010; 11 (Supplement)**, (2010).
10. Cutting, K. *J Community Nurs* **22(11): 34**, (2008).
11. White, R. *Wounds UK* **4 (1)**, (2008).
12. Lapioli-Zufelt, A. *et al. Journal of Wound Ostomy & Continence Nursing* **25**, 314-6, (1998).
13. Spitz, C. *et al. Handchir Mikrochir Plast Chir* **30**, 71-81, (1998).
14. Schumann, H., Beljan, G., Hoping, D., Bruckner-Tuderman, L., (2005).
15. Denyer, J. The use of atraumatic wound dressings in epidermolysis bullosa. Poster presentation at the European Wound Management Association conference. Prague, Czech Republic, 2006.

Table 1. Examples of the clinical use/outcomes

Type	Mölnlycke products used	Clinical Outcomes	Ref
Not stated	Mepitel®	A young girl with EB lesions. Mepitel adhered to the surrounding skin, with atraumatic removal.	12
EC32	Mepitel®	Young boy with EB. Re-epithelialisation occurred quickly, and hand function was largely restored. Mepitel® secured intravenous cannulae without blistering around the insertion site.	13
EC32	Mepitel®	Mepitel was used to manage bullae and to secure intravenous cannulae without blistering around the insertion site.	7
All types	Mepilex®	22 patients aged between 1 and 91 years with bullous skin diseases (13 with EB and 9 patients with acquired bullous conditions) treated with a Mepilex® dressing. Good wound healing was reported in the majority of patients. Minimal pain was experienced during dressing changes and no allergic reactions occurred.	14
EC32	Mepitel® and Mepilex® Transfer	Healing for neonate occurred after three weeks with dressing protection.	15
EC31	Mepilex®	A 10-year-old with EB who had blisters and erosions at the urethral meatus. Prevention and re-stenosis of the urethral meatus were accomplished with Mepilex. There was no recurrence after 10 months.	16
General	Mepitac® and Mepitel®	Used as a tape with neonates where extreme care was required. When compared to using silver salts in a randomized study, wounds healed faster, were less painful and required fewer dressing changes.	17
All types	Mepilex® Transfer, Mepitel® and Mepilex® Lite	Used on paediatric wounds, the dressings were well tolerated, improved healing, reduced peri-wound maceration and facilitated patient independence.	18 19,20
All types	Mepilex®	Face protection when using mask ventilation for delivering anaesthesia to patients with EB.	21
All types	Mepilex®, Mepitac®, Mepilex® Border and Mepilex® Border Lite	Prevented sticking to wound with cushioning in easily traumatised areas.	22
All types	Mepilex®, Mepitac®, Mepilex® Border and Mepilex® Border Lite	Prevented sticking to wound with cushioning in easily traumatised areas.	22
EC32	Mepilex®	Applied to forehead, zygomatic arch, and eyelids before eye surgery. No iatrogenic complications observed. Improved visual function at 24 months of age.	23
All types	Mepilex® Transfer and Mepitac®	Used in skin grafting in EB patients.	24
All types	Mepitel®	In chronic EB wounds, a collagen dressing was used underneath Mepitel®, and pain relief was observed when changing from Adaptic to Mepitel®.	25
EC32	Mepitel®	Reduced pain, increased comfort, and enhanced quality of life for an adult male.	26
EC31	Mepilex® Transfer	Wound almost completely healed over approximately 18 months.	2
EC32	Mepitel® and Mepilex® Transfer	'Remarkable' improvement of wounds after 4 weeks.	2
EC32	Mepilex® Transfer	Used to cover a wound treated with Oleogel and as a control.	27
EC30, EC31, EC32	Mepitel®, Mepilex® Border Lite, Mepitac® and Tubifast®	Observational study on EB patients. 10 of 19 respondents reported to use Mepilex® Transfer. 7 answered questions regarding the performance and safety of this with satisfactory ratings. The thin silicone-based foam dressing (Mepilex® Border Lite) and the tubular retention bandage (Tubifast®) had been used by 89% and 53% of respondents, respectively.	28

Table 2. Product Exposure

Product Name	Relative EB sales, (Based on the questionnaire to key markets and internal knowledge) Score from 5 (largest EB sales) to 1 (lowest EB sales)	Product Launch date (Year)	Number of years of product in market
Mepilex® Transfer	5	2002	16
Mepilex® Lite	4	2004	13
Mepitel®	3	1989	31
Mepilex®	2	1999	19
Tubifast®	2	2006	11
Mepitac®	2	2004	13

16. Rubin, A. I. *et al. International Journal of Dermatology* **46**, 1076-7, (2007).
17. Baharestani, M. M. *Ostomy Wound Management* **53(6):34-55.**, (2007).
18. Ly, L. *et al. Journal of Wound Care* **17**, 482-92, (2008).
19. Schober-Flores, C. *Journal of the Dermatology Nurses' Association* **1**, (2009).
20. Weiner, M. S. *Ostomy Wound Manage* **50**, 13-4, (2004).
21. Meola, S. *Paediatr Anaesth* **18:11**, 1109-11, (2008).
22. Lara-Corrales, I. *et al. Pediatric Dermatology* **27**, 229-37, (2010).
23. Motley W.W., V. D. K., West C.E. *Journal for the American Association for Paediatric Ophthalmology and Strabismus* **14(3):283-284**, (2010).
24. Yuen, W. Y. *et al. J Am Acad Dermatol* **68**, 93-7.e2, (2013).
25. Gorell, E. S. *et al. Pediatric Dermatology* **32**, 220-5, (2015).
26. Downe, A. *Wounds UK*; **3(1):46-53.**, (2017).
27. Schwieger-Briel, A. *et al. Dermatology Research and Practice* **2017**, 10, (2017).
28. Mölnlycke® Health Care data on file, Cross-sectional observational study report EB, PD-566181 Rev 01 (2019)